LearningRadiology.com

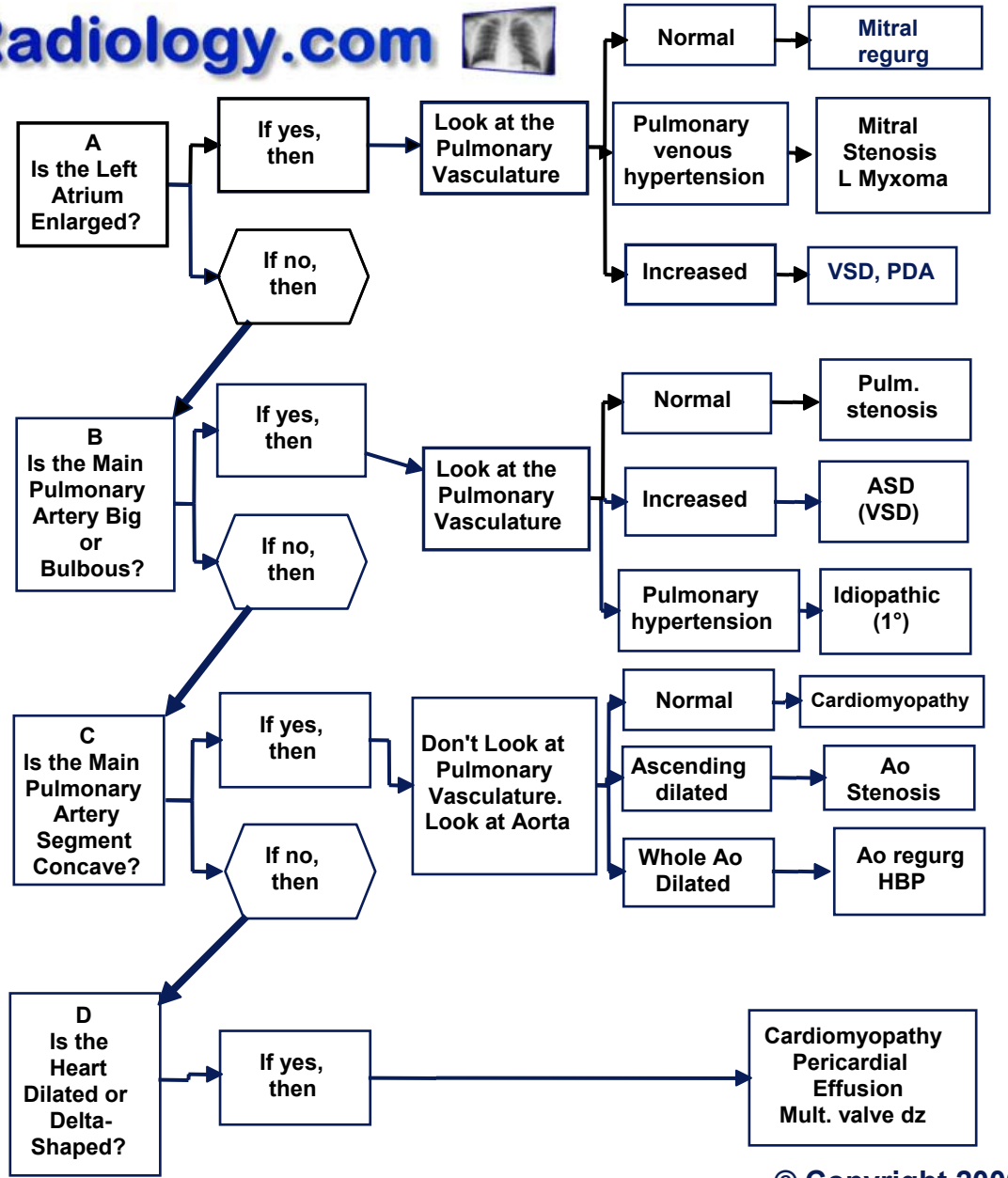

© Copyright 2000 William Herring, MD